

Postinfectious coronavirus disease 2019 hemorrhagic cerebellitis: illustrative case

Eric K. H. Chow, MSc,¹ Barry M. Rabin, MD,² and John Ruge, MD³

¹Chicago Medical School, Rosalind Franklin University of Medicine and Science, Chicago, Illinois; and Departments of ²Neuroradiology and ³Pediatric Neurosurgery, Advocate Lutheran General Hospital, Chicago, Illinois

BACKGROUND Conditions that can mimic posterior fossa tumors are rare. Their identification is crucial to avoid unnecessary surgical intervention, especially when prompt initiation of medical therapy is critical.

OBSERVATIONS The authors presented a case of pseudotumoral hemorrhagic cerebellitis in a 3-year-old boy who presented initially with headache, persistent vomiting, and decreased level of consciousness 9 weeks after severe acute respiratory syndrome coronavirus 2 infection. Magnetic resonance imaging showed a left cerebellar hemorrhagic mass-like lesion with edema and mild hydrocephalus. The patient responded to high-dose steroids and was discharged 2 weeks later with complete recovery.

LESSONS When evaluating patients with possible tumor syndromes, it is important to also consider rarer inflammatory syndromes that can masquerade as neoplasms. Postinfectious hemorrhagic cerebellitis is one such syndrome.

<https://thejns.org/doi/abs/10.3171/CASE22219>

KEYWORDS pseudotumor hemorrhagic cerebellitis; COVID-19; SARS-CoV-2

Conditions that can mimic brain tumors or vascular malformations are rare. The appropriate identification of them is crucial to avoid unnecessary surgical intervention, especially when they may respond to medical therapy. In the posterior fossa, acute cerebellitis is an autoimmune inflammatory syndrome that is usually distinguishable from tumoral process by its symmetric bilateral involvement of the cerebellum.^{1,2} This syndrome predominantly affects children and can occur concurrently with infection, after infection, or after vaccination.¹ The typical presentation is with headache, vomiting, and declining level of consciousness in a child; ataxia may also be present.³ Radiographically, T2-weighted magnetic resonance imaging (MRI) reveals bilaterally symmetric cerebellar hyperintensity, cerebellar edema, and possible obstructive hydrocephalus.¹ Treatment is with high-dose steroids, and most patients make a full recovery.

Although typically bilateral, acute cerebellitis has been reported to present unilaterally as well and is termed hemicerebellitis.⁴ Cases of pseudotumoral hemicerebellitis, with symptoms and radiographic features that mimic space-occupying lesions, have also been reported.⁵⁻⁷

Pseudotumoral hemicerebellitis can be challenging to diagnose and treat appropriately because it presents with mass effect suggestive of neoplasm. Cerebellar hemorrhage can also result in mass effect and obstructive hydrocephalus and may be caused by vascular malformations, fistulas, or, rarely, complication of occult neoplasms;⁸ however, hemorrhage is not a recognized feature of acute cerebellitis.⁹

In this paper, we report a case of pseudotumoral hemorrhagic cerebellitis with an initial presentation that was highly suggestive of posterior fossa neoplasm, for which we nearly considered surgical intervention. We highlight this case to bring awareness to pseudotumoral syndromes that may be the cause for a patient presenting with symptoms of possible tumor. We also report a review of the literature for other similar cases.

Illustrative Case

A 3-year-old boy with a history of severe acute respiratory syndrome coronavirus 2 (SARS-CoV-2) infection of 3 weeks' duration, with onset 9 weeks prior, presented to our hospital with mild headache,

ABBREVIATIONS ADEM = acute disseminated encephalomyelitis; AHLE = acute hemorrhagic leukoencephalitis; COVID-19 = coronavirus disease 2019; CSF = cerebrospinal fluid; EVD = external ventricular drain; HSV = herpes simplex virus; MRI = magnetic resonance imaging; RBC = red blood cell; WBC = white blood cell.

INCLUDE WHEN CITING Published September 5, 2022; DOI: 10.3171/CASE22219.

SUBMITTED May 17, 2022. **ACCEPTED** June 28, 2022.

© 2022 The authors, CC BY-NC-ND 4.0 (<http://creativecommons.org/licenses/by-nc-nd/4.0/>).

recurrent vomiting of 2 days' duration, and increasing somnolence in the day prior to admission. The patient also had congestion, rhinorrhea, mild fever, and fewer wet diapers. In the emergency department, the patient was somnolent, and complete blood count demonstrated a baseline microcytic anemia (hemoglobin 5.8; mean corpuscular volume 55; red cell distribution width 26.6), thrombocytopenia (platelets lowest at 67,000/mm³ and 121,000/mm³ on admission), and leukocyte counts within normal pediatric range (white blood cell [WBC] 11.9; absolute lymphocytes 2.5).

Infectious disease workup was negative for SARS-CoV-2/influenza/respiratory syncytial virus serology. The parents reported that rapid at-home antigen test results were positive at the time of symptomatic coronavirus disease 2019 (COVID-19) infection in the patient. Cerebrospinal fluid (CSF) analysis showed red blood cell (RBC) count of 2,000, WBC count of 7, 65% segmented neutrophils, 28% lymphocytes, polymorphonuclear leukocytes, no organisms, and negative culture. Meningitis/encephalitis panels were negative. Subsequent respiratory and gastrointestinal pathogen panels were also negative. Despite fluids, RBC transfusion, antiemetics, and famotidine, the patient continued to be lethargic and had recurrent vomiting.

Computed tomography of the brain revealed a left cerebellar hemorrhagic mass-like lesion with temporal horn dilation indicating early hydrocephalus (Fig. 1A), which prompted neurosurgery consultation on day 2. MRI showed vasogenic edema in the left cerebellar hemisphere

and vermis with mass effect on the fourth ventricle (Fig. 1B–D). There was no restricted diffusion. There was no solid contrast enhancement, although there was mild foliaform enhancement (Fig. 1E), suggesting a mass or tumor such as pilocytic astrocytoma or other low-grade tumor. Magnetic resonance angiography/magnetic resonance venography showed no aneurysm, high-flow vascular malformation, or dural sinus thrombosis. Susceptibility-weighted imaging confirmed the hemorrhagic nature of the lesion (Fig. 1F).

We involved our hematology-oncology colleagues; however, CSF cytology for abnormal cells was negative, serum alpha-fetoprotein and serum/CSF beta human chorionic gonadotropin were negative, and MRI of the spine demonstrated no drop metastasis.

Given the clinical presentation and imaging findings, we determined with the neuroradiologist that the patient had a postinfectious hemorrhagic cerebellitis. Dexamethasone 0.25 mg/kg was started on day 2 and led to almost immediate clinical improvement with no headache 24 hours after starting the steroids. External ventricular drain (EVD) was considered; fortunately, the patient was stable on observation prior to recognizing the mild hydrocephalus and rapidly responded to medical therapy alone. Dexamethasone was maintained throughout the hospital course and the patient was weaned in the last 2 days.

The patient improved clinically and was hemodynamically stable for discharge after 15 days. On follow-up with our clinic 1.5 months

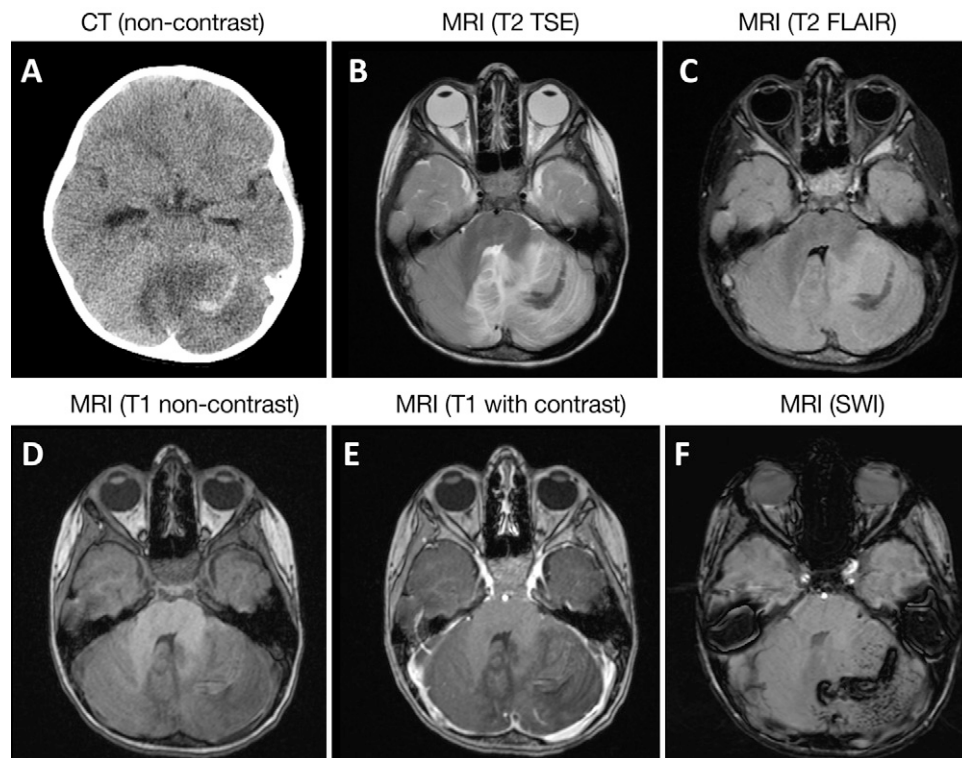


FIG. 1. Radiological findings of hemorrhagic cerebellitis in a 3-year-old boy with a history of SARS-CoV-2 infection 9 weeks prior, presenting with 2 days of recurrent vomiting and increasing somnolence. Computed tomography (A) showed a hypodense left cerebellar mass-like lesion with curvilinear hyperdensity believed to be blood. T2 turbo spin echo (B) and fluid-attenuated inversion recovery (C) imaging demonstrated edema, involvement of the cerebellar vermis, and hydrocephalus (not shown). T1 pre- (D) and postcontrast (E) show foliaform enhancement without solid mass. Susceptibility weighted imaging (F) confirms the hemorrhagic nature.

later, the patient had made good recovery and had a normal neurological examination. Follow-up MRI at that time demonstrated complete resolution of the swelling and edema of the cerebellum with small residual chronic hemorrhage but no evidence of hydrocephalus.

Literature Review

We searched PubMed for other cases of hemorrhagic cerebellitis using the terms “hemorrhagic OR hemorrhage” AND “cerebellitis.” We included papers that were published in 2000 and later; were available in English; included adult or pediatric patients; were case reports, case series, or cohort studies; and had hemorrhagic findings on imaging occurring concurrently with cerebellitis.

Our search returned 14 references from PubMed (Fig. 2); 9 papers were excluded based on the above criteria. After reviewing the papers, we decided to exclude 3 more papers that described cases of cerebellar hemorrhage; however, they were associated with recognizable infectious syndromes that did not present any diagnostic conundrum (*Plasmodium falciparum*,¹⁰ *Acanthamoeba*,¹¹ HSV encephalitis¹²). The two papers that met inclusion criteria described cases of postinfectious hemorrhagic cerebellitis that presented similarly to our case. Singh et al.⁹ reported a case of pseudotumoral hemicerebellitis with hemorrhage in a 12-year-old boy presenting with headache, vertigo, rash, cough, and recurrent vomiting who had typhoid fever 2 weeks prior. Bonduelle et al.¹³ reported a case of acute hemorrhagic leukoencephalitis (AHLE), also known as Weston-Hurst syndrome, with concurrent cerebellar involvement in a 25-year-old woman who presented with ataxia and drowsiness and became comatose shortly after admission and who had an influenza-like illness 3 weeks prior. Data for these reported cases and our current case are summarized in Table 1.

Discussion

Observations

In this report, we describe pseudotumoral hemorrhagic cerebellitis in a 3-year-old who presented with persistent vomiting, headache, and declining level of consciousness. In our review of the literature, we found two other cases of postinfectious hemorrhagic cerebellitis.^{9,13} The patients were young in all cases (ranging from 3 to 25 years in age) and pediatric in both cases of isolated cerebellitis

with hemorrhage. Headache, persistent vomiting, and declining level of consciousness were common symptoms in the pediatric cases; these presenting symptoms were also common to pseudotumoral hemicerebellitis without hemorrhage described in the review by Vivekanandan et al.⁵

MRI findings were similar between our case and that of Singh et al.,⁹ both appearing pseudotumoral, with unilateral hyperintensity of MRI T2 and fluid-attenuated inversion recovery, cerebellar edema, herniation, and resulting hydrocephalus. Again, these radiographic findings were similar to those reported in pseudotumoral hemicerebellitis without hemorrhage.¹⁴ The similarities in presenting symptoms, clinical course, radiographic findings, and outcome suggest that pseudotumoral hemicerebellitis and hemorrhagic cerebellitis may be due to the same underlying autoimmune mechanisms.

In our case, the patient responded well to steroid therapy alone and made a complete recovery without the need for temporary CSF diversion or surgical decompression. In the case reported by Singh et al.,⁹ the patient also received an EVD for ascending transtentorial herniation and hydrocephalus. Similarly, EVD has been used to manage hydrocephalus in other cases of cerebellitis.^{15,16} In deciding whether steroids alone will be adequate or if CSF diversion is also necessary, we suggest considering the severity of CSF obstruction, hydrocephalus, and clinical decline. In our case, the fourth ventricle remained patent and hydrocephalus was mild, leading us to pursue conservative management.

Of interest, our patient was admitted with low-normal platelet count ($166,000/\text{mm}^3$) and was thrombocytopenic throughout his stay, with platelets as low as $54,000/\text{mm}^3$ and with brief response to platelet transfusion. Interestingly, Singh et al. also reported low platelets ($110,000/\text{mm}^3$) in their patient with pseudotumor hemicerebellitis with hemorrhage. Other reports of pseudotumoral hemicerebellitis have not reported platelet levels or the presence of thrombocytopenia. It is possible that involvement of platelets in the autoimmune response may be related to the hemorrhagic variant that we report, distinguishing it from pseudotumoral hemicerebellitis.

While we include the AHLE case with concurrent cerebellar hemorrhage reported by Bonduelle et al., it differed from our case (and cases of pseudotumoral hemicerebellitis for that matter) in that

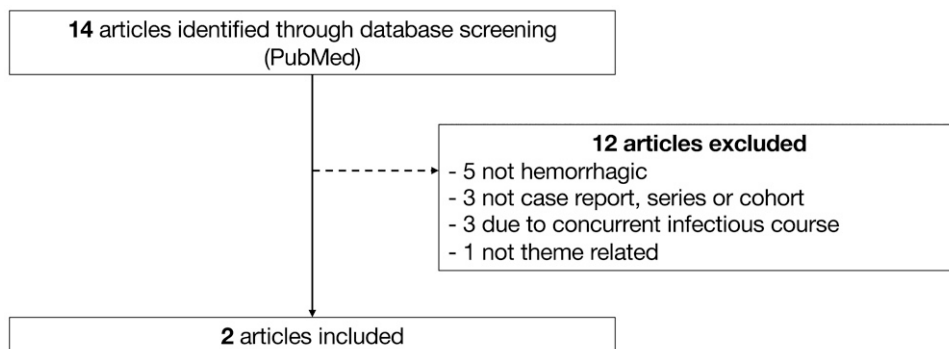


FIG. 2. Literature review. PubMed was searched using (“hemorrhagic” OR “hemorrhage”) AND “cerebellitis,” and articles were screened by the primary author. The following inclusion criteria (determined a priori) were included: (1) published after January 1, 2000, and available in English; (2) included adults or pediatric patients; (3) were case reports, case series, or cohort studies; and (4) had hemorrhagic findings on imaging occurring concurrently with cerebellitis. After reviewing the references, an additional three papers were excluded because they described cases of cerebellar hemorrhage associated with recognizable infectious syndromes.

TABLE 1. Cases of hemorrhagic cerebellitis

Factor	Present Case	Singh et al., 2012 ⁹	Bonduelle et al., 2018 ¹³
Age (yrs)/sex	3/M	12/M	25/F
Etiology	Postinfectious: SARS-CoV2 9 wks prior (3-wk duration, positive rapid home antibody test)	Postinfectious: typhoid fever 2 wks prior	Postinfectious: influenza-like illness 3 wks prior, concurrent AHLE
Symptoms	Mild headache, recurrent vomiting, increasing somnolence, congestion, rhinorrhea, mild fever	Severe headache, recurrent vomiting, vertigo, rash, cough, neurological deterioration, seizure, nystagmus	Headache, ataxia, drowsiness, became comatose
Platelets ($\times 1,000/\text{mm}^3$)	54–166*	110	Not reported
Laterality	Unilateral	Unilateral	Bilateral, symmetric
MRI findings	Pseudotumoral, herniation, & hydrocephalus	Pseudotumoral, herniation, & hydrocephalus	Herniation & hydrocephalus
Treatment	Steroids, pRBC transfusion	Antibiotics, acyclovir, high-dose steroids, EVD placement	Ventriculoperitoneal diversion, decompressive craniectomy, acyclovir, amoxicillin, cefotaxime, steroids, plasma exchange
Outcome	Complete recovery, discharged in 2 wks	Complete recovery, discharged in 4 wks	Transferred to rehabilitation center at 2 mos w/ progressive regain of walking & minimal neuro-deficits

pRBC = packed RBC.

* Platelets were $166,000/\text{mm}^3$ on admission and $67,000/\text{mm}^3$ on day 1; lowest platelet count was $54,000/\text{mm}^3$ on day 8.

the patient was a young adult, had a longer stay, and experienced a more difficult recovery. Furthermore, MRI findings with the case reported by Bonduelle et al. demonstrated symmetric bilateral involvement that was not suggestive of neoplasm. Similar to how AHLE may be regarded as a hemorrhagic variant of acute disseminated encephalomyelitis (ADEM),¹⁷ one could hypothesize that hemorrhagic cerebellitis may be a more severe hemorrhagic variant of cerebellitis. This may just be a contrast of convenience, however, because we have not observed any trend to suggest that hemorrhagic cerebellitis has poorer outcomes than cerebellitis in the manner that AHLE has poorer outcomes than ADEM.

This may be the first reported case of hemorrhagic postinfectious cerebellitis associated with COVID-19; however, several cases of cerebellitis without hemorrhage have already been reported in association with SARS-CoV-2.^{18–20} SARS-CoV-2 has known neurotropism with a variety of manifestations,^{21,22} including but not limited to acute hemorrhagic necrotizing encephalitis,²³ stroke,²⁴ multisystemic inflammatory syndrome in children,^{25,26} cerebellar ataxia,²⁷ and acute cerebellitis.^{18–20} It does not come as a surprise that SARS-CoV-2 may play some role in the development of cerebellitis, but whether the hemorrhagic variety that we are reporting is more likely with COVID-19 versus other viral or bacterial infections will likely remain an unanswered question.

Lessons

While acute cerebellitis is easily discerned by its bilaterally symmetric presentation, pseudotumoral hemicerebellitis with or without hemorrhage can be a diagnostic challenge in patients who present with symptoms suggesting a posterior fossa tumor.

Radiographically, our case presented with many MRI features suggesting a tumor: a unilateral cerebellar lesion, involvement of the vermis,

and associated edema and mass effect causing hydrocephalus. In fact, the initial impression of our radiologist was that infiltrative or low-grade tumors could be diagnostic considerations, despite the lack of any obvious solid mass enhancement. Although uncommon, hemorrhage may occur in 8% of pilocytic astrocytomas.²⁸ The additional finding of hemorrhage in our case adds to the ruse of pseudotumoral cerebellitis; however, as discussed in previously reported cases, specific features that may differentiate pseudotumoral cerebellitis from tumors include the lack of a well-defined nodular lesion¹⁴ and foliaform enhancement along the cerebellar folia (Fig. 1E).^{6,14}

As we evaluate patients with possible tumor syndromes, it is important that we also consider infrequently seen inflammatory syndromes that can masquerade as neoplasms. Postinfectious hemorrhagic cerebellitis is one such syndrome that may present with clinical symptoms and radiographic findings that suggest a cerebellar tumor. Correct diagnosis of this imposter syndrome can prevent unnecessary surgical intervention, especially when conservative management with high-dose steroids alone is likely to result in complete recovery.

References

- De Bruecker Y, Claus F, Demaerel P, et al. MRI findings in acute cerebellitis. *Eur Radiol.* 2004;14(8):1478–1483.
- Yildirim M, Gocmen R, Konuskan B, Parlak S, Yalnizoglu D, Anlar B. Acute cerebellitis or postinfectious cerebellar ataxia? Clinical and imaging features in acute cerebellitis. *J Child Neurol.* 2020;35(6):380–388.
- Connolly AM, Dodson WE, Prensky AL, Rust RS. Course and outcome of acute cerebellar ataxia. *Ann Neurol.* 1994;35(6):673–679.
- Carceller Lechón F, Duat Rodríguez A, Sirvent Cerdá SI, et al. Hemicerebellitis: report of three paediatric cases and review of the literature. *Eur J Paediatr Neurol.* 2014;18(3):273–281.
- Vivekanandan A, Santyr B, Ranger A. Effects of systemic corticosteroid treatment on pseudotumoral hemicerebellitis: a case

- report and literature review. *Childs Nerv Syst.* 2021;37(6): 2105–2113.
6. Jabbour P, Samaha E, Abi Lahoud G, et al. Hemicerebellitis mimicking a tumour on MRI. *Childs Nerv Syst.* 2003;19(2):122–125.
 7. Iester A, Alpigiani MG, Franzone G, Cohen A, Puleo MG, Tortori-Donati P. Magnetic resonance imaging in right hemisphere cerebellitis associated with homolateral hemiparesis. *Childs Nerv Syst.* 1995;11(2):118–120.
 8. Santi M, Kadom N, Vezina G, Rushing EJ. Undiagnosed medulloblastoma presenting as fatal hemorrhage in a 14-year-old boy: case report and review of the literature. *Childs Nerv Syst.* 2007;23(7):799–805.
 9. Singh P, Bhandal SK, Saggar K, Pooni PA, Jaswal RS. Pseudotumoral hemicerebellitis with hemorrhage. *J Pediatr Neurosci.* 2012; 7(1):49–51.
 10. Hashemi N, Callon LM, Kumar KS. Malaria retinopathy and cerebellitis in a 9-year-old boy in the United States. *J AAPOS.* 2015; 19(1):87–89.
 11. Modica S, Miracco C, Cusi MG, et al. Non-granulomatous cerebellar infection by *Acanthamoeba* spp. in an immunocompetent host. *Infection.* 2018;46(6):885–889.
 12. Hassan H, Thomas B, Iyer RS. Insights from a rare clinical presentation of herpes simplex encephalitis: adding to the catatonic dilemma? *Neurologist.* 2011;17(2):114–116.
 13. Bonduelle T, Stricker J, Minéo JF, et al. Weston-Hurst syndrome with acute hemorrhagic cerebellitis. *Clin Neurol Neurosurg.* 2018; 173:118–119.
 14. de Mendonca JLF, Barbosa H, Viana SL, Freitas FMO, Viana MACB, Ferreira ACL. Pseudotumoral hemicerebellitis: imaging findings in two cases. *Br J Radiol.* 2005;78(935):1042–1046.
 15. Amjad N, Haque A, Ahmed K. Acute cerebellitis with hydrocephalus. *J Coll Physicians Surg Pak.* 2014;24(suppl 2):S127–S128.
 16. Waqas M, Hadi YB, Sheikh S, Shamim SM. Acute cerebellitis successfully managed with temporary cerebrospinal fluid diversion using a long tunnel external ventricular drain: a long-term radiological follow-up of two cases. *BMJ Case Reports.* 2016;2016: bcr2016215631.
 17. Gibbs WN, Kreidie MA, Kim RC, Hasso AN. Acute hemorrhagic leukoencephalitis: neuroimaging features and neuropathologic diagnosis. *J Comput Assist Tomogr.* 2005;29(5):689–693.
 18. Sharma S, Ruparelia J, Bhaskar S, Tiwari S, Nag VL, Panda S. Acute fulminant cerebellitis in children with COVID-19 infection: a rare but treatable complication. *Pediatr Neurol.* 2021;119:45–47.
 19. Sotgiu S, Uzzau S, Pippia A, Carta A, Antonucci R. Expanding the spectrum of acute cerebellitis due to SARS-Cov-2. *Pediatr Neurol.* 2021;121:1–2.
 20. Moreno-Escobar MC, Feizi P, Podury S, et al. Acute cerebellitis following SARS-CoV-2 infection: a case report and review of the literature. *J Med Virol.* 2021;93(12):6818–6821.
 21. Lin JE, Asfour A, Sewell TB, et al. Neurological issues in children with COVID-19. *Neurosci Lett.* 2021;743:135567.
 22. Han Y, Yuan K, Wang Z, et al. Neuropsychiatric manifestations of COVID-19, potential neurotropic mechanisms, and therapeutic interventions. *Transl Psychiatry.* 2021;11(1):499.
 23. Mullaguri N, Sivakumar S, Battineni A, Anand S, Vanderwerf J. COVID-19 related acute hemorrhagic necrotizing encephalitis: a report of two cases and literature review. *Cureus.* 2021;13(4):e14236.
 24. Nannoni S, de Groot R, Bell S, Markus HS. Stroke in COVID-19: a systematic review and meta-analysis. *Int J Stroke.* 2021;16(2): 137–149.
 25. Schupper AJ, Yaeger KA, Morgenstern PF. Neurological manifestations of pediatric multi-system inflammatory syndrome potentially associated with COVID-19. *Childs Nerv Syst.* 2020;36(8): 1579–1580.
 26. Toraih EA, Hussein MH, Elshazli RM, et al. Multisystem inflammatory syndrome in pediatric COVID-19 patients: a meta-analysis. *World J Pediatr.* 2021;17(2):141–151.
 27. Povlow A, Auerbach AJ. Acute cerebellar ataxia in COVID-19 infection: a case report. *J Emerg Med.* 2021;60(1):73–76.
 28. White JB, Piepgras DG, Scheithauer BW, Parisi JE. Rate of spontaneous hemorrhage in histologically proven cases of pilocytic astrocytoma. *J Neurosurg.* 2008;108(2):223–226.

Disclosures

The authors report no conflict of interest concerning the materials or methods used in this study or the findings specified in this paper.

Author Contributions

Conception and design: Ruge. Acquisition of data: Chow. Analysis and interpretation of data: Chow. Drafting the article: all authors. Critically revising the article: all authors. Reviewed submitted version of manuscript: Ruge, Chow. Approved the final version of the manuscript on behalf of all authors: Ruge. Statistical analysis: Chow. Administrative/technical/material support: Ruge, Chow. Study supervision: Ruge.

Correspondence

John Ruge: Advocate Lutheran General Hospital, Advocate Children's Hospital, Park Ridge, IL. john.ruge@aah.org.